



DATE PRESENTING CLINICAL SIGNS

1.6.26

PATIENT

Belle Post

SPECIES

Feline

BREED

DSH

SEX

FS

AGE

12.13.12

WEIGHT

9.4lbs

INTERPRETED BY

Maggie Machen Lamy,
DVM, DACVIM
(Cardiology)

HOSPITAL NAME

Cat Sense Feline
Hospital

REFERRING VET

Dr. Sinclair

INVOICE

46320

History: Recheck echo. Presented in October 2025 for decreased appetite and for vomiting. The owner said she also had noticed PU/PD. The vomiting was determined to be due to a string that she vomited but bloodwork showed her creatinine at that time was 1.5 and her BUN was 23. Her T4 was at the very high end of normal at 4.7 in October and a thyroid profile run in early December showed she was definitely hyperthyroid. She was started on 1.25mg methimazole twice daily and she just had her initial 2-week recheck and bloodwork. She had been placed on Mirataz in October to help stimulate her appetite and she still requires daily Mirataz or alternating Mirataz and Cerenia + cyproheptadine to maintain her appetite. She had not gained any weight, and her heart murmur had gone from a 1/6 to a 2-3/6 murmur. Her HR was 200, which was slightly higher than she often has been (usually around 188-192ish). Her BUN had increased to 74 and creat to 5.2. This past weekend her appetite and attitude decreased more.

-Pertinent abnormal PE/Chem/CBC/UA Results (10/21/25): BUN=23, creat=1.9, SDMA=15. 1/3/26: BUN=74, creat=5.2, SDMA=39

-Current medications: Methimazole 1.25mg bid, Alternating: Mirataz SID and then 24 hours later gets Cerenia 4mg SID and cyproheptadine 1mg BID for 24 hours then Mirataz again... (because the Mirataz is causing irritation in the ears)

-Sedation used: Not required to complete full diagnostic ultrasound.

-Pertinent previous ultrasound results (6/8/2021 MML): Normal/remodeling. Suspect physiologic murmur.

-STAT: Not requested.

-Imaging performed by: Stephanie Warga RDCS, RVT.

ECHOCARDIOGRAM FINDINGS

2D, m-mode, color flow and doppler imaging is available. The left ventricular wall is normal in dimension. There is a diffusely hyperechoic endocardium consistent with age-related fibrosis. Minimal remodeling. The papillary muscles are hyperechoic. The left atrium is normal in size. The right atrium is normal in size. The right ventricle appears normal. The mitral valve is normal in structure and mobility. Trace MR. The tricuspid valve appears normal in structure and mobility. No TR. Blood flow through both the LVOT and RVOT are normal in velocity. No effusions. No obvious cardiac tumors.

CARDIAC CHART

FELINE CARDIAC PARAMETERS	BODY WEIGHT (kg)	HR (BPM)	IVSd (cm) (Moise, Pipers)	LVIDd (cm) (Moise, Pipers)	LVWd (cm) (Moise, Pipers)	FS (%)	EF (%)
NORMAL PARAMETER	-----	150-240	3.5-0.55	<2 (mean 1.5)	3.5-0.55	35-67	80-100
PATIENT	4.3	NM	0.51	1.2	0.52	48	82
FELINE CARDIAC PARAMETERS	LA/AO (Boon)	LA/AO HEART BASE (Swe) (Abbott)	LA 2D short axis Base view (cm) (Abbott)		LVOT VEL (m/s)	RVOT VEL (m/s)	E max (m/s)
NORMAL	<1.5	<1.3	<1.2		<1.6	<1.3	<0.9
PATIENT	NM	1.1	1.2		1.1	1.3	NM

Adapted from June Boon, Veterinary Echocardiography, 1998
Abbott J & MacLean H JVIM 2006;20: 111-119, Moise et al. Am J Vet Res 47:1476, 1986. Pipers et al. Am J Vet Res 40:882, 1979.

INTERPRETATION OF THE FINDINGS & FURTHER RECOMMENDATIONS

Persistently normal cardiac structure and function. No evidence of HCM phenotype and no cause for the murmur is apparent. The LA remains normal, suggesting low risk for complication. No additional issues are seen.

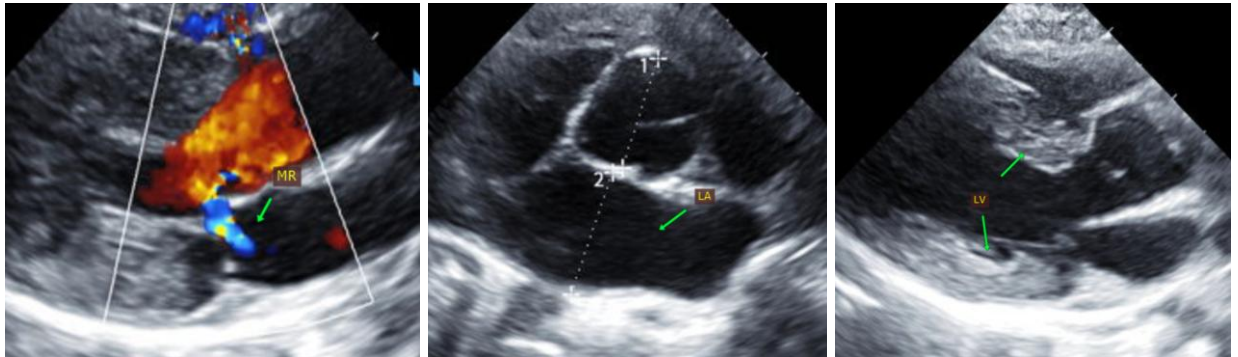
Given these findings, no medications are indicated. Prognosis is open.

No cardiac contraindication for general anesthesia. Should fluid or steroid therapy be indicated in the future, any cat should be monitored for intolerance (changes in RR/RE).

Monitor at home for signs of cardiac compromise, including respiratory changes and/or signs of a blood clot event (paralysis, neurologic changes).

Recommend recheck echocardiogram in 1 year to assess for any progressive issues or development of disease the pre-existing murmur may mask.

IMAGES



The information and recommendations provided are based on the images presented by the referring veterinarian. No evaluation can be communicated regarding pathology that was not visible in the image/video clips provided.

Thank you for this referral. This report was generated using transcription software, and minor dictation errors may be present. If the clinical or image interpretation does not parallel your findings or if I can be of any further assistance, please contact me.

Maggie Machen Lamy, DVM
Diplomate of the American College of Veterinary Internal Medicine (Cardiology)
info@sonopath.com